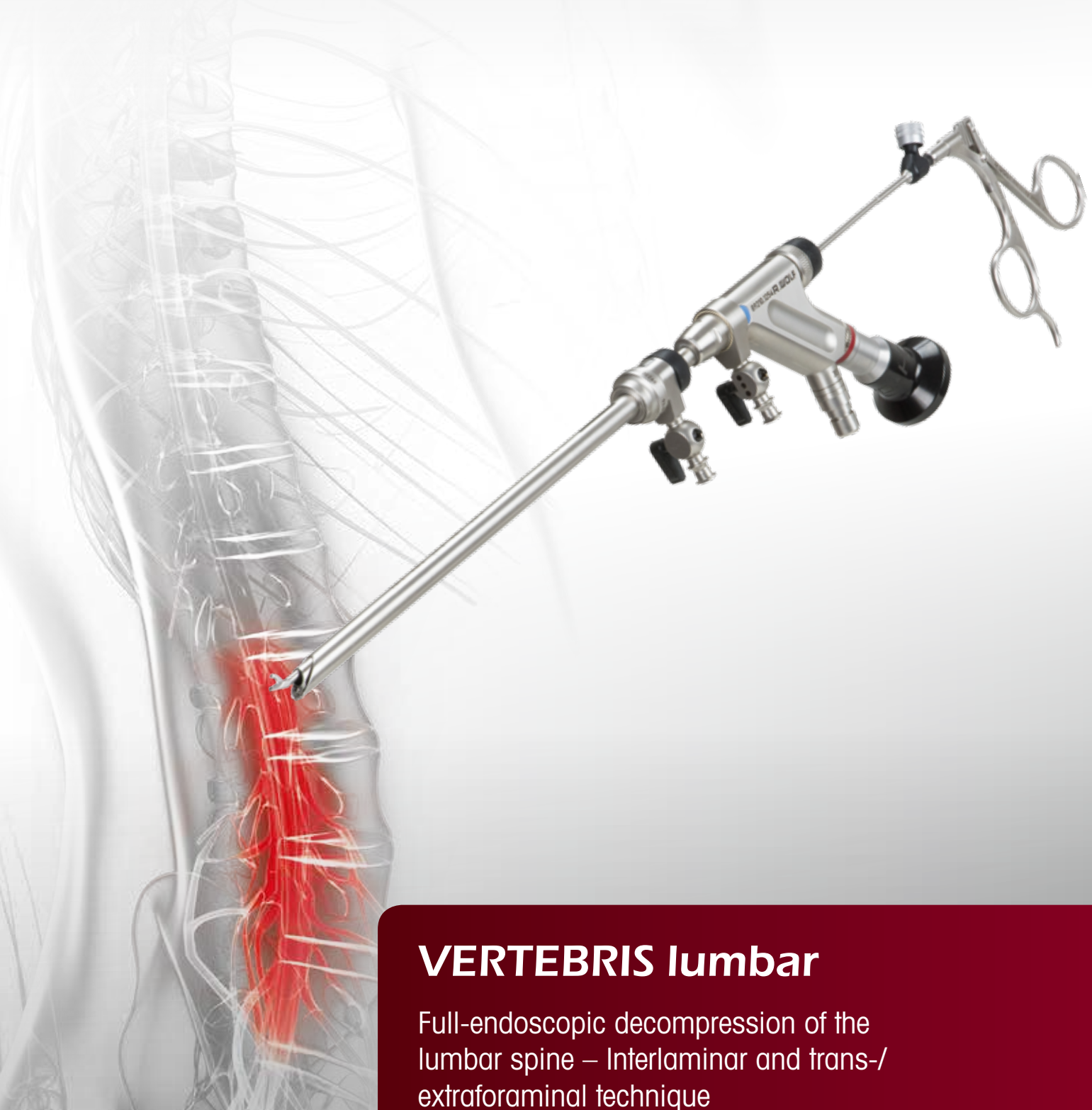

Takes the pressure



VERTEBRIS lumbar

Full-endoscopic decompression of the lumbar spine – Interlaminar and trans-/extraforaminal technique

VERTEBRIS lumbar

Full-endoscopic Spine Instrument Set

Contents

VERTEBRIS lumbar	
■ Foreword	04
The full-endoscopic trans- and extraforaminal technique	
■ Positioning	08
■ Determination of the lateral access	08
■ Implementation of the lateral access	09
■ Operating procedure	12
■ Implementation of the posterolateral access	13
■ Implementation of bony resection	14
■ Implementation of the extraforaminal access	15
The full-endoscopic interlaminar technique	
■ Positioning	19
■ Determination of the access	19
■ Implementation of the access	20
■ Operating procedure	21
■ Implementation of bony resection	24
VERTEBRIS lumbar overview	
VERTEBRIS lumbar Instrument Set	
■ VERTEBRIS lumbar transforaminal and extraforaminal	26
■ VERTEBRIS lumbar interlaminar technique	28
■ VERTEBRIS lumbar transforaminal posterolateral	30
■ Instrument Set optional	32
■ Radioblator RF 4 MHz – Multidisciplinary Radiofrequency Surgical System	36
■ Universal Motor System	38
■ FLUID CONTROL Arthro-Spine – Innovative Fluid Management System	41

Literature

VERTEBRIS lumbar

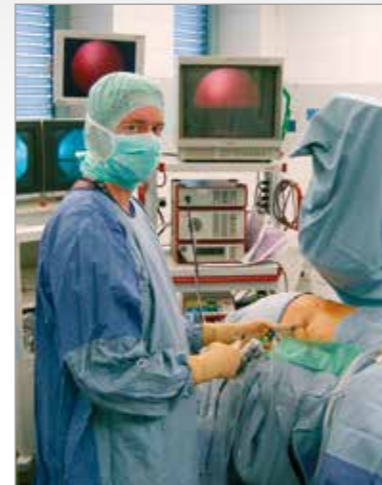Foreword

Musculoskeletal pain ranks among the most frequent reasons for seeking medical help. Degenerative diseases of the spine form a daily focus. The therapy encompasses medical and socioeconomic challenges.

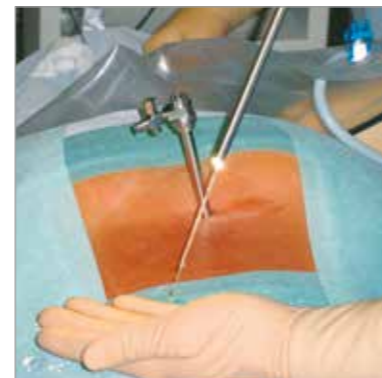
After conservative measures have been exhausted, surgical intervention may be necessary in circumstances of exacerbated pain or neurological deficits. In spite of good therapeutic results from conventional operations, consecutive damage may result from traumatization. It is therefore important to continuously optimize the procedures and workflows. The latest research results and technical innovations need to be critically assessed and used constructively in order to facilitate the best treatment strategies. The aim in this process of continuous improvement is to minimize the trauma induced by the operation and negative long-term effects while observing existing quality standards.

Minimally invasive techniques allow tissue damage and its consequences to be reduced. Endoscopic operations carried out during a continuous flow of fluid demonstrate advantages which these procedures standard practice in many areas. Over the past 20 years, transforaminal procedures with posterolateral access have been used in the area of the lumbar spine. The working area is mainly intradiskal, as well as involving an intraforaminal and extraforaminal approach. Since 1998, our Center for Spine Surgery and Pain Therapy has therefore been developing a transforaminal and an interlaminar access in order to reach the spinal canal full-endoscopically. These expand the indication spectrum and permit an equivalent approach in vision that is comparable with conventional operations taking account of the indication criteria, which offer all the advantages of a genuine, minimally invasive procedure.

Problems on the technical side emerged as a result of the availability of optical systems with a small intraendoscopic working channel and the correspondingly restricted repertoire of instruments. Insurmountable difficulties were liable to arise in respect of the resection of hard tissue, the resection of hard tissue, the surgical access passage, and mobility. Adequate work on the pathology was technically limited and had to be carried out in part without direct visualization. The developed of new rod-lens telescopes with an intraendoscopic 4.1 mm working channel and hence new instruments, as well as shavers and burrs was therefore necessary. This enabled working under continuous, excellent visual conditions. Adequate bony resection was also facilitated for the first time. This expanded the principal indication spectrum to spinal disk herniations, spinal stenoses and stabilizing methods.



Lateral access for the full-endoscopic transforaminal operation



A continuous flow of fluid permits outstanding intraoperative visual conditions

Full-endoscopic surgery on the lumbar spine has now achieved an established status within the overall concept of surgery. Taking due account of the indication criteria, it provides an adequate and safe complement or alternative to conventional surgery. Full-endoscopic operations are also possible on the cervical and thoracic spine.

A change is taking place for the first time as a result of the latest technical developments and new access passages, which appears to be the start of a radical new departure comparable with the establishment of arthroscopic interventions in joints. Nevertheless, conventional and maximally invasive operations will continue to be indispensable in spine surgery today and in the future. Surgeons must be able to perform such operations so that they are in a position to deal safely with any problems and complications that may emerge during full-endoscopic interventions as in any other invasive procedure.

The development of full-endoscopic methods should not be evaluated as a replacement for existing standard operations but as a complementary procedure and alternative within the overall concept of spine surgery.

Dr. med. Martin Komp

Priv.-Doz. Dr. med. habil. Sebastian Ruetten



The telescopes in the current generation have a large 4.1 mm intraendoscopic channel



The development of new instruments offers expanded opportunities for implementation

Center for Spine Surgery and Pain Therapy
Head: Priv.-Doz. Dr. med. habil. Sebastian Ruetten



ST. ELISABETH GRUPPE
KATHOLISCHE KLINIKEN RHEIN-RUHR

Center for Orthopedics and Traumatology

of the St. Elisabeth Group – Catholic Hospitals Rhein-Ruhr

St. Anna Hospital Herne/Marien Hospital Herne University Hospital/Marien Hospital Witten

Director: Prof. Dr. med. Georgios Godolias

VERTEBRIS lumbar

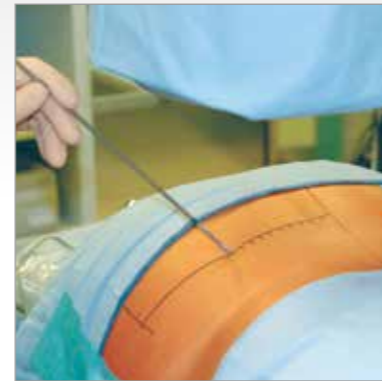
VERTEBRIS lumbar

The full-endoscopic transforaminal and extraforaminal technique

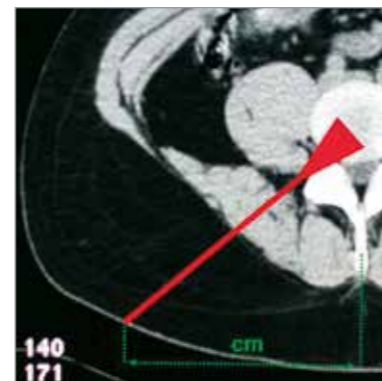
Details of percutaneous operations on lumbar disks to achieve intradiskal decompression were published at the beginning of the 1970s. Optical systems dedicated to inspection of the intervertebral space following an open operation have been used since the early 1980s. A full-endoscopic approach was subsequently developed using a transforaminal technique. In anatomical terms, this means accessing the intervertebral disk in a posterolateral to lateral approach within the area of the intervertebral foramen between the exiting and traversing spinal nerves without the need for resection of bony or ligament structures. The entry point in the skin for the surgical access passage is defined in centimeters from the midline. The applications are generally carried out for intradiskal or extradiskal foraminal therapy. Intradiskal volume and pressure reduction is intended to achieve reduced compression due to the intervertebral disk. Removal of the intraforaminal and extraforaminal intradiskal material is technically possible. Sequestered material located within the spinal canal generally only be resected retrograde intradiskally through the annulus defect. This is carried out within the scope of an "In-out technique".

Nucleus material is located within the spinal canal posterior to the annulus level in the anterior epidural space medial to the medial pedicle line. It frequently reaches to the mid-line or the contralateral side. Clinical experience indicates that the annulus defect is frequently smaller than the diameter of the sequester volume. Furthermore, there is no continuous connection intradiskally in the majority of cases. In cases of advanced disk degeneration or older spinal disk herniations, the sequester frequently does not comprise a contiguous substance. Removal in such cases is not possible in a single piece. These factors frequently prevent the retrograde resection carried intradiskally of sequestered nucleus material. Direct access to the extradiskal ventral epidural space with continuous visualization is hence necessary for adequate decompression.

The most frequent localization of lumbar disk herniations relates to the lower levels. The diameter of the intervertebral foramen decreases from the cranial to caudal position. An additional constriction can be caused by degenerative changes. These anatomical conditions frequently prevent extradiskal access to the anterior epidural space with full visualization when using the posterolateral access passage particularly at the lower levels. There are also technical limits



The established posterolateral access is measured in centimeters from the midline



The working area is primarily intradiskal in the posterolateral access

to a lateral alignment of the endoscope in order to reach the spinal canal tangentially after implementing the access as a result of the approach access passage within the soft tissue and the zygoapophyseal joint. The predictable adequate decompression by means of the posterolateral access may therefore be significantly restricted.

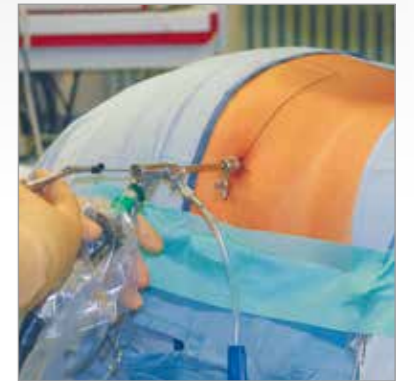The new transforaminal passage has therefore been developed in the past several years. *

This approach does not entail measurement in centimeters being carried out to define the entry point in the skin, but involves an individual anatomical determination under radiographic control. The access permits the spinal canal to be reached tangentially and hence affords direct visualization of the epidural space with a continuous flow of fluid for purposes of adequate decompression. A broad but clearly defined indication spectrum is provided in conjunction with the newly developed endoscopes designed with a large working channel and the corresponding new instruments, shavers and burrs.

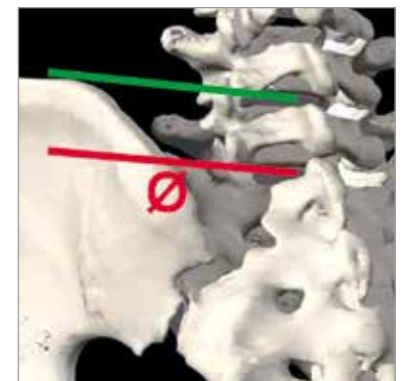
Mobility in a caudal direction to the middle of the pedicle and in a cranial direction to the commencement of the pedicle serves as a guide for decompression within the spinal canal. Constricted foramina no longer constitute restrictions but can be expanded. The pelvis can prevent the necessary lateral access so that the center of the cranially positioned pedicle should be reached maximally in the orthograde lateral beam path. At the upper levels, there are limits to the laterality of the access due to the organs of the thorax and abdomen. The increase in size of the foramen in a cranial direction and the possibility of bone resection achieves a larger radius of action so that the access can be selected less laterally. There are no restrictions for intraforaminal and extraforaminal decompression. Selection of a lateral access is also attempted here in order to be able to pass under the exiting spinal nerves atraumatically. The surgical access method for intraforaminal or extraforaminal spinal disk herniations and in foraminal stenoses may vary from the conventional approach in order to avoid damaging the dislocated nerves or exiting nerves which cannot be localized with certainty. This relates to the extraforaminal access.

In the case of the intradiskal approach, e.g. in the case of fusions or infections, the posterolateral access is frequently necessary. The access always depends on the target point and takes into account individual pathology and anatomy. Outside the indication criteria, there are well-defined limits to the transforaminal procedure.

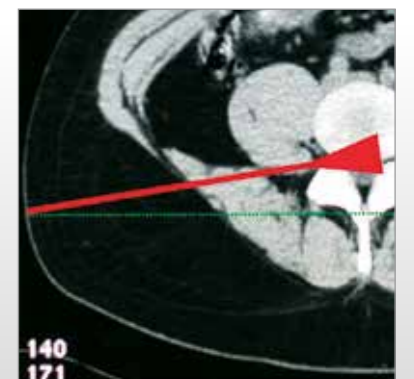
* see literature



The lateral transforaminal access allows the spinal canal to be reached in the caudal levels



The pelvis can prevent the necessary lateral transforaminal access at the lower levels



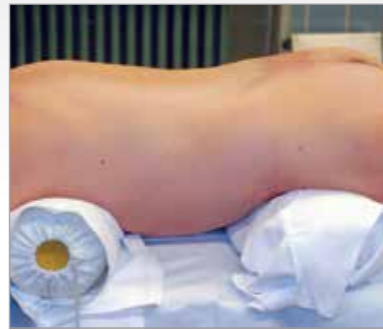The lateral transforaminal access shifts the working area into the spinal canal working area

VERTEBRIS lumbar

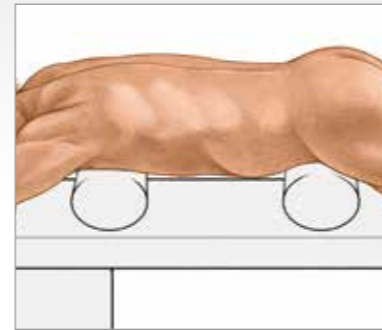
The full-endoscopic transforaminal technique

Positioning

The patient is in the prone position lying on a hip and thorax roll on an X-ray permeable table. Application of a C-arc is required during the operation.

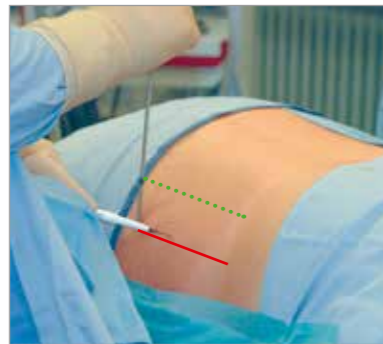


Prone position with pelvic and thorax rolls

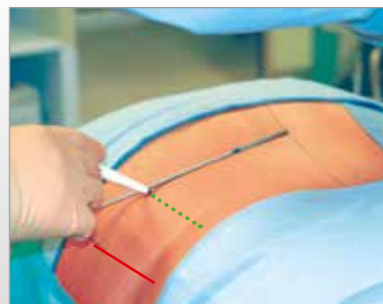
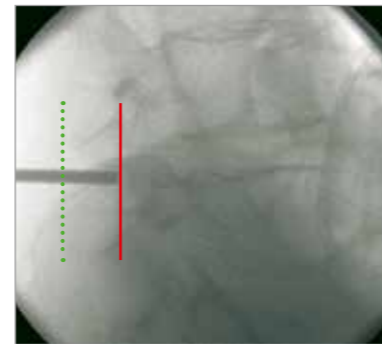


Determination of the lateral access

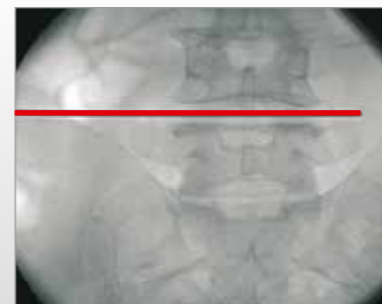The access is determined under image intensifier control on the basis of anatomical landmarks in the orthograde lateral and posterior-anterior beam path and taking account of the pathology. Posterior limitation of the facet joints (red line). It is recommended to mark the posterior limitation of the spinous process (green line) as entry point of the puncture cannula. Depending on the level, injury to the abdominal organs must be excluded.



Determination of the maximum anteriority on the basis of individual anatomical landmarks and drawing the entry line in the skin – posterior limitation of the facet joints (red line)




Establishment of the spinal disk level in the orthograde posterior-anterior beam path and definition of the entry point

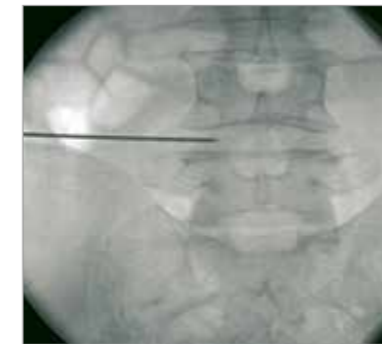

Implementation of the lateral access

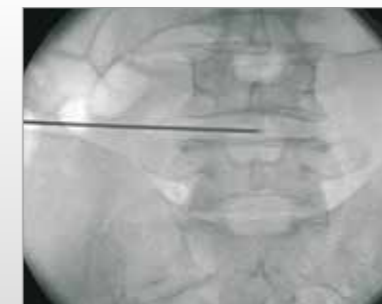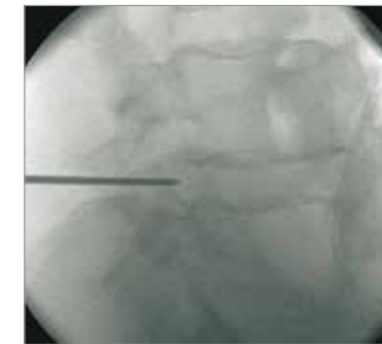
After determining the entry point in the skin and carrying out a stab incision, a spinal cannula is inserted under lateral image intensifier control and with conservation of the neural structures. The positioning in relation to the spinal canal is carried out individually in relation to the spinal canal. The guide wire is then inserted and the spinal cannula is removed.



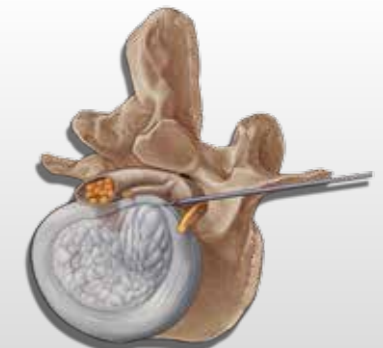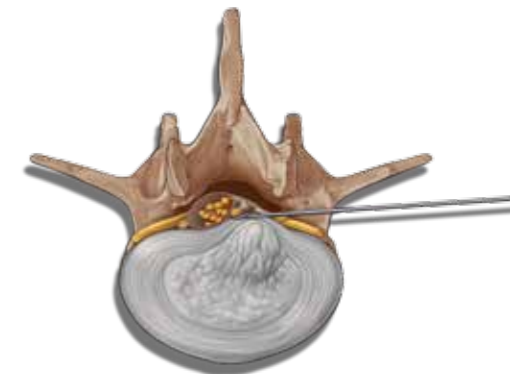
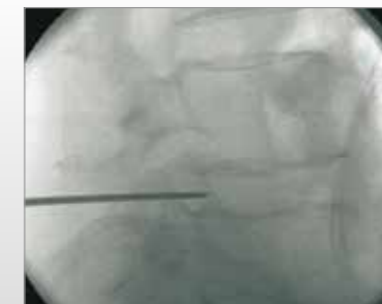Inserted spinal cannula



At the start of the spinal canal, the spinal cannula contacts the posterior annulus in the medial pedicle line



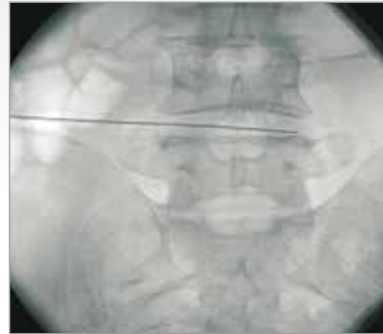The spinal cannula is pushed in the posterior annulus in the direction of the spinal canal




VERTEBRIS lumbar

The full-endoscopic transforaminal technique

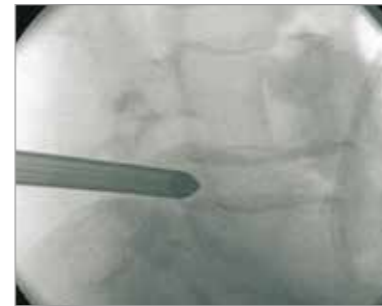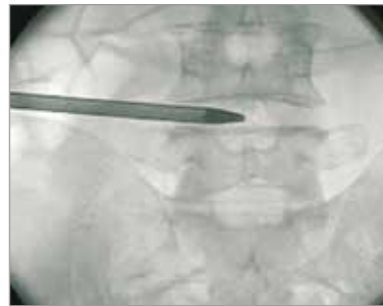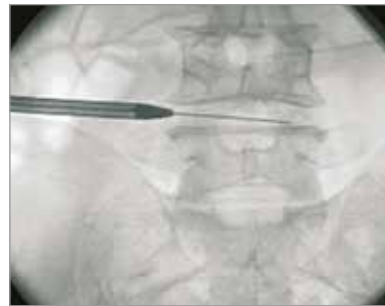The dilator is initially inserted along the guide wire by means of rotating movements initially as far as the foramen and after removal of the guide wire it is inserted in the spinal canal depending on the pathology. The beveled working sleeve is then pushed along the dilator and the dilator is removed. All the work stages must be carried with protection of the neural structures.



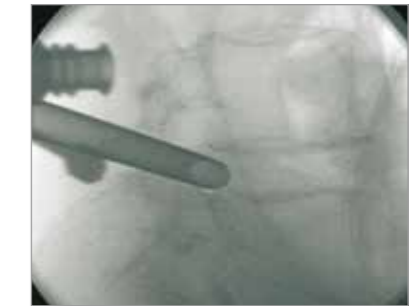
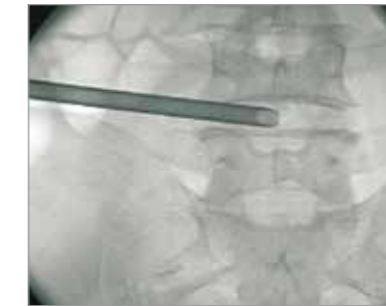
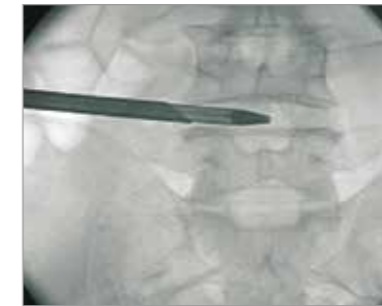
The guide wire is positioned and the spinal cannula is removed



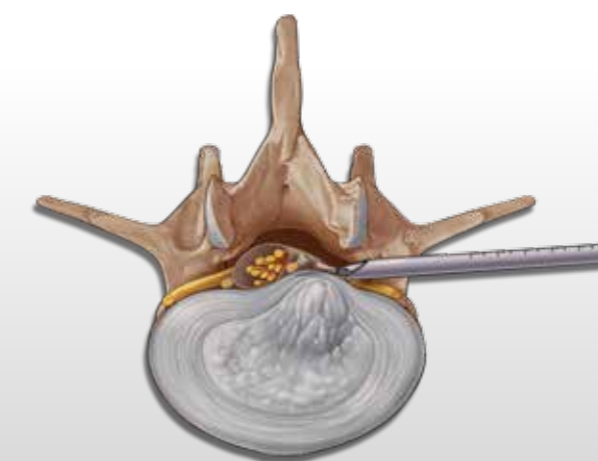
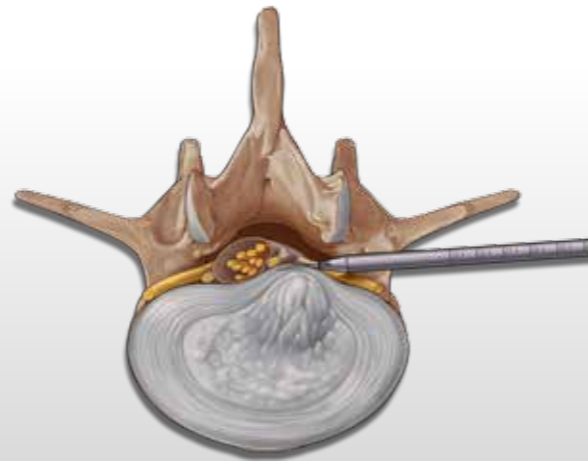
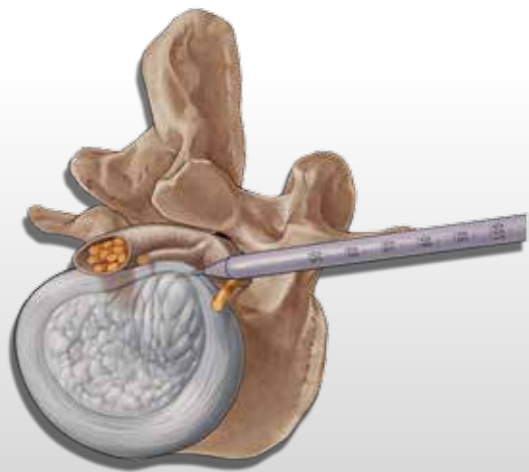
Lateral transforaminal access



The dilator is inserted along the guide wire and in the final position is located in the spinal canal or posterior annulus defect



The working sleeve is positioned along the dilator and the dilator is removed; the beveled opening is located within the spinal canal posterior to the annulus



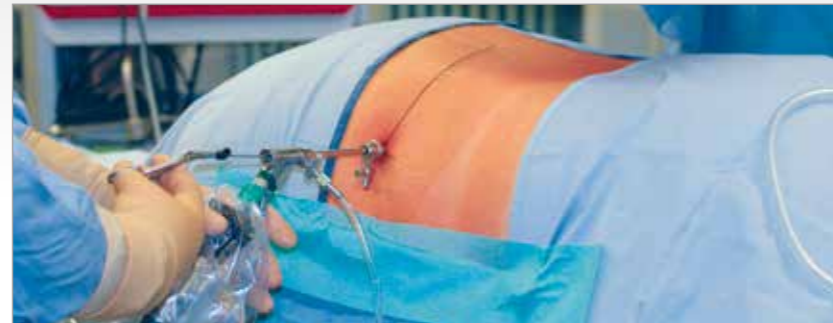VERTEBRIS lumbar

The full-endoscopic transforaminal technique

Operating procedure

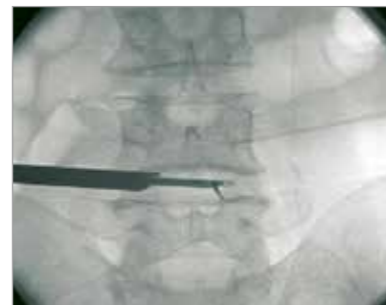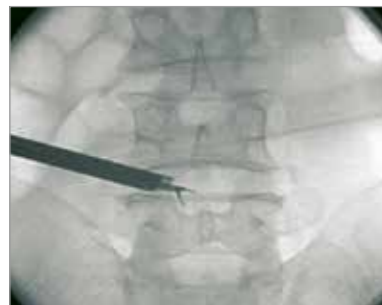The endoscope is inserted through the working sleeve. The operation is carried out in vision using different instrument sets positioned through the intraendoscopic working channel and with a continuous flow of liquid.

The locking caps for the telescope and working sleeve should only be used briefly if bleeding obscures visibility since when operations last a long time and the drainage of fluid is prevented without being noticed, the consequences of volume over-



load and elevated pressure within the spinal canal and the associated and neighboring structures cannot theoretically be completely excluded. Experience indicates that generally

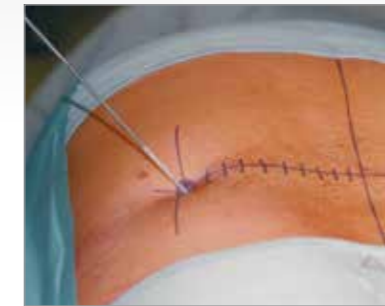speaking there is an increased risk of complications occurring when all new procedures are carried out, in particular during the learning curve.



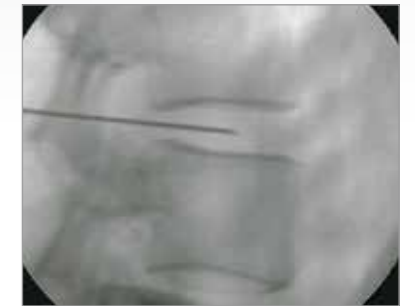The lateral access permits working the spinal canal in vision

Implementation of the posterolateral access

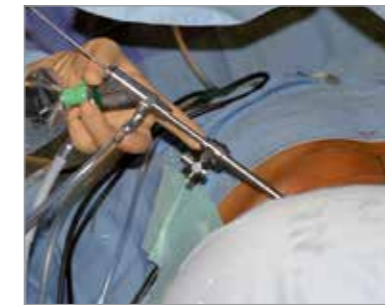In intradiskal operations, prevention of a lateral access through the pelvic or for avoidance of injuries to the abdominal or thoracic organs at the cranial levels, a more posterior to postero-lateral access may be necessary. The entry point in the skin is determined by the pathology and anatomy, and can be measured in centimeters from the midline. Alternatively it is localized by adequate positioning of the inserted spinal cannulas. The subsequent stages with insertion of the guide wire, the dilator, the operating sleeve and then the telescope are not different from the procedure already described.



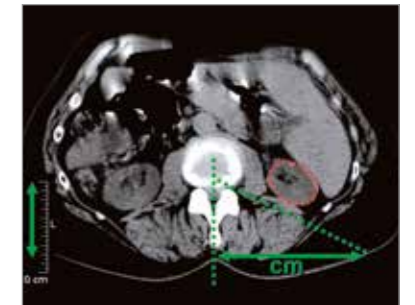
Measurement of the entry point in centimeters laterally from the midline



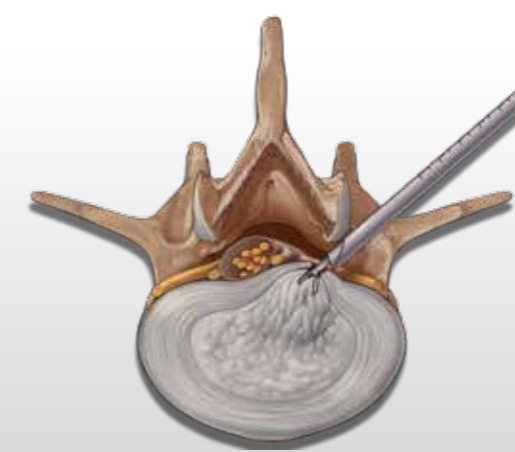
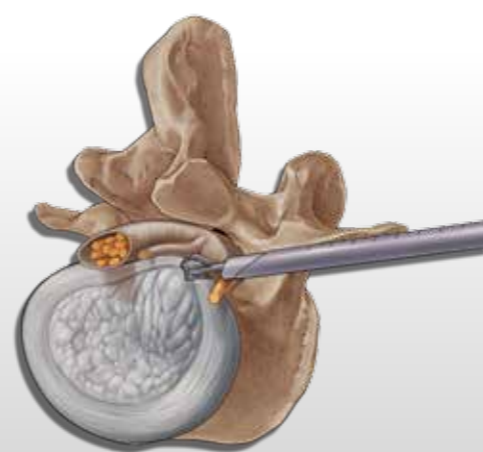
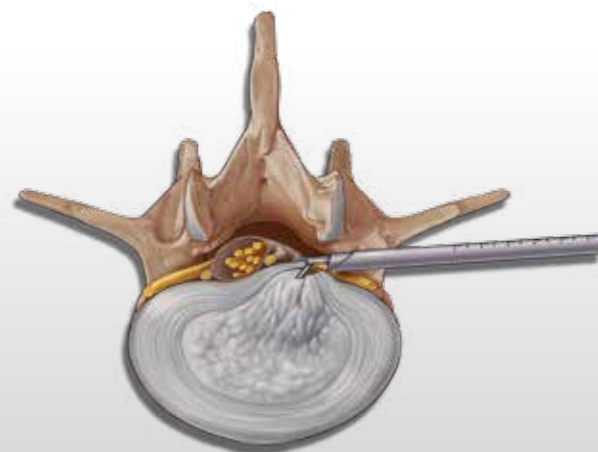
The inserted spinal cannulas in the desired target point can determine the localization of the stab incision



Operation with posterolateral transforaminal access



The maximum laterality of the access can be measured on the basis of a preoperative CT scan in order to avoid injury to organs



VERTEBRIS lumbar

The full-endoscopic **transforaminal** technique

Implementation of bony resection

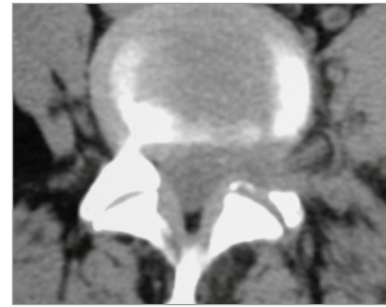
Bone resection may be necessary in order to expand mobility within the spinal canal or if there are problems during access. This may be the case e.g. in degenerative and position-related foramen stenosis or during an operation on recess stenosis. The entry point into the skin is possible

from posterolateral to lateral. After the transforaminal or extraforaminal access has been implemented, the bony structures have to be dissected for this. This generally involves resection of the anterior structures of the ascending facets. If a resection of the structures of the caudal pedicle

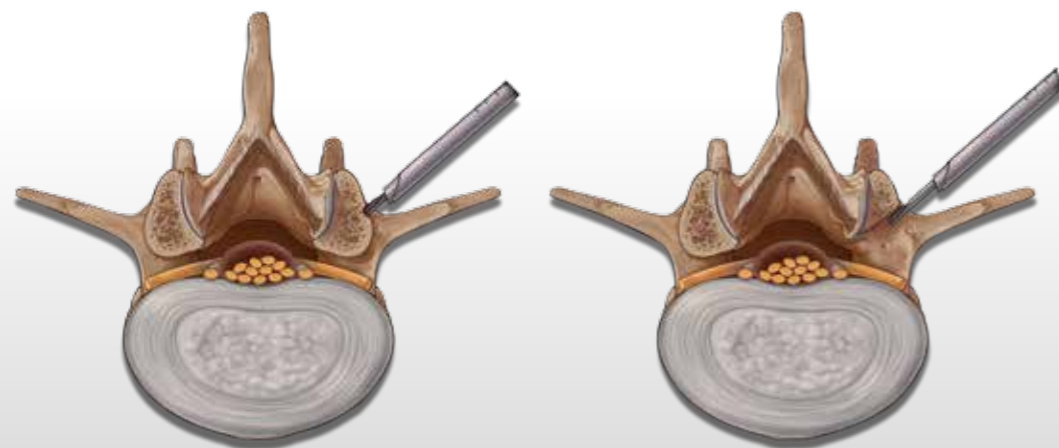
is carried out, it is important to take account of the fact that this is a support structure. Extensive resections can lead to biomechanical weaknesses and to pedicle breaks.



A range of burrs or bone punches is available for bone resection



An opening of the joint cannot always be avoided in order to reach medial edge of the ascending facet



Bone resection generally relates to the anterior structures of the ascending facets

VERTEBRIS lumbar

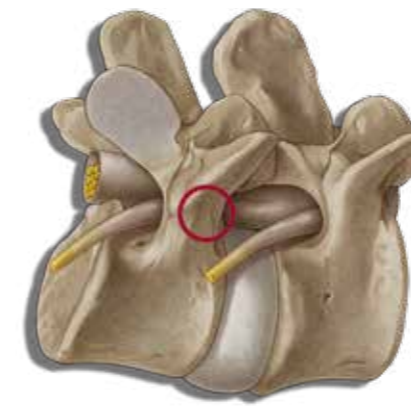
The full-endoscopic **extraforaminal** technique

Implementation of the extraforaminal access

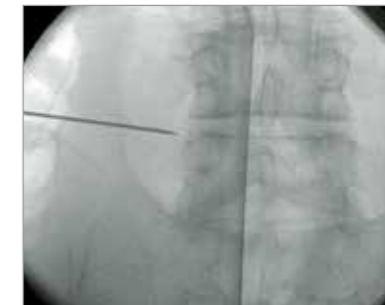
In the case of intraforaminal and extraforaminal spinal disk herniations and foraminal stenoses, there may be an increased risk of injury to the exiting nerves during the passage through the foramen with the access instrument set. The extraforaminal access may be necessary here. The entry point into the skin is possible from posterolateral to late-

ral. The spinal cannula is not guided through the foramen into the spinal canal but on the caudal pedicle of the level to be operated. This is the safest zone in relation to the exiting nerves and an access-related risk is avoided. The guide wire, dilator and operating sleeve are then also inserted on to the pedicle up to the bony contact. The anatomical structures of

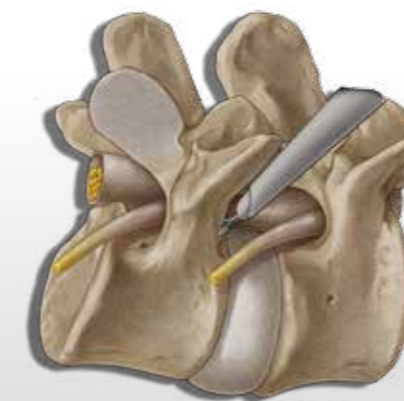
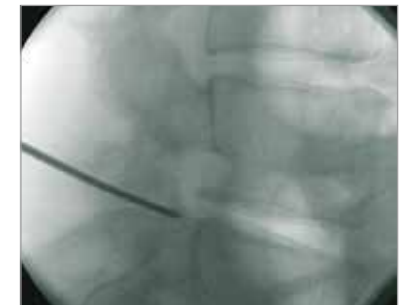
the caudal foramen and the exiting nerve can then be dissected in vision and the surgical intervention can be carried out with conservation of the nerves.



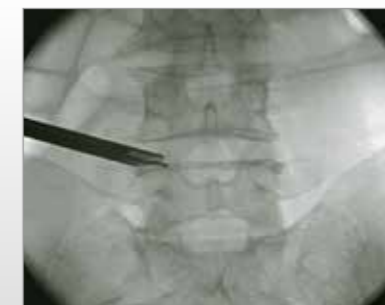The caudal pedicle is a safe zone in relation to the exiting nerve



Insertion of the spinal cannula on to the caudal pedicle



Dissection of the anatomical structures of the caudal foramen and the exiting spinal nerve



VERTEBRIS lumbar

VERTEBRIS lumbar

The full-endoscopic interlaminar technique

Direct access to the epidural space with continuous visualization is hence necessary for adequate operations within the spinal canal. A lateral access is necessary for this when using the full-endoscopic transforaminal technique. The bony and neural boundaries of the neuroforamen define limits for mobility and hence also in relation to the indication criteria. Furthermore, the necessary lateral access in the lower levels may be prevented by the pelvis. On the basis of our experience, these restrictions encompass a spectrum of pathologies which are not operable using the full-endoscopic transforaminal approach due to technical limitations.

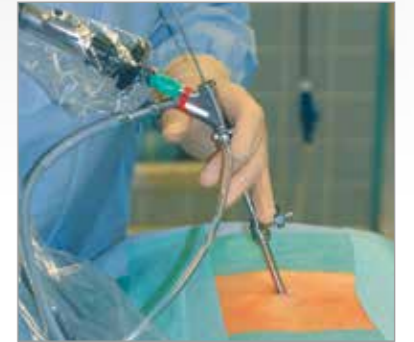Making use of anatomically preformed access areas is effective for reducing surgically related traumatization to the structures of the spinal canal. Alongside the intervertebral foramen, the sacral hiatus and the interlaminar window are located here. Resection of large pathologies is not possible in technical terms using epiduroscopy through the sacral hiatus. The surgical access through the interlaminar window is therefore used. This has been familiar in lumbar spine surgery for the longest and is frequently used. It has been described since the beginning of the 1920s. Alternative methods were subsequently developed, such as the posterolateral approach for taking biopsies from vertebrae at the end of the 1940s or intradiskal decompression using chemonucleolysis in the early 1970s. Endoscopic inspections of the intervertebral space after open decompression were described during the early 1980s. The implementation of full-endoscopic operations concentrated on the transforaminal technique with posterolateral access.

Since the end of the 1970s, the microsurgical procedure using the microscope has also been developed and today this has achieved the status of "Gold Standard" for interlaminar decompression in the area of the spinal canal. Details of an endoscopically assisted technique known as a microendoscopic operation were published in the late 1990s. This relates to visualization of the opened operation site using an endoscope and a monitor.

Opening the spinal canal is necessary in the conventional method for reaching the epidural space. This generally involves incision of the ligamentum flavum and resection of bone. Adequate access must be created which ensures vision into the spinal canal and permits working with instruments. Problems may arise as a result of traumatization of the access passage, as a result of resection of stabilizing structures and in particular in relation to potential revisions resulting from scar formation. The microscope principally reduces the size of the access passage and creates very good light and envisioning conditions. Resection of structures of the spinal canal can generally not be avoided. Access using the microendoscopic method may be structured to be more gentle on tissue than the microscopic procedure. The advantage is in the smaller distance between the working area and the visualizing system. Visibility conditions and illumination are generally poor. This is not an endoscopic procedure in the true sense. Today, the microendoscopic access method and the microendoscopic operating procedure are partly combined. Overall, a larger access generally has to be selected with all procedures than would actually be necessary for actually working in the spinal canal.

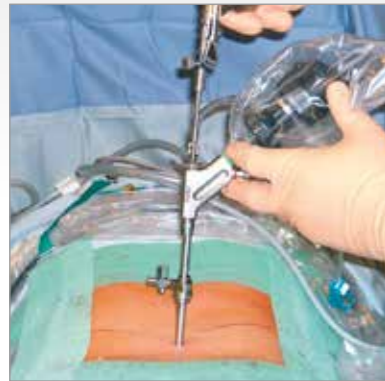In order to make use of the known advantages from the transforaminal operation and arthroscopy, the new fullendoscopic interlaminar access was developed over recent years.*

* see literature

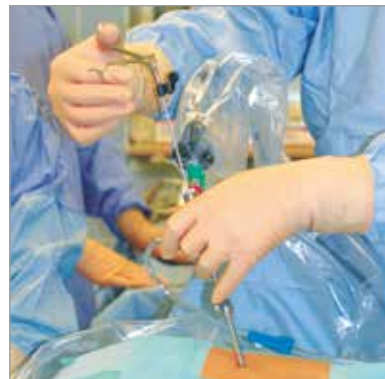

VERTEBRIS lumbar

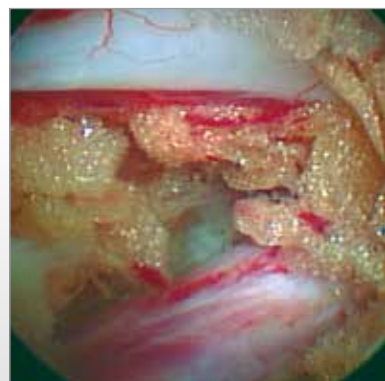
The full-endoscopic interlaminar technique



Full-endoscopic interlaminar access



Handling the telescope using the joystick principle permits mobility



The interlaminar access guarantees outstanding visibility for the structures of the spinal canal

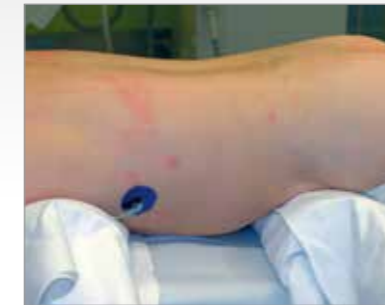The light and imaging system with 25° direction of view is located directly in the relevant working area so that traumatization can be minimized in the access passage and also in connection with the structures of the spinal canal. Working in a continuous flow of liquid provides excellent visibility conditions. Mobility for the new endoscope is achieved by handling with joystick technology. Protection of the neural structures is provided by manipulating the beveled operating sleeve like a nerve hook. In combination with the newly developed instrument sets, this represents a genuine minimally invasive procedure.

Indications primarily relate to pathologies within the spinal column. It is important to note that the size of the interlaminar window can prevent free passage of the endoscope. In this case, the bone can be cut until the target point is reached without opening the ligamentum flavum or damaging the zygoapophyseal joints. In most cases, bony resection should be avoided, although the pathology precludes

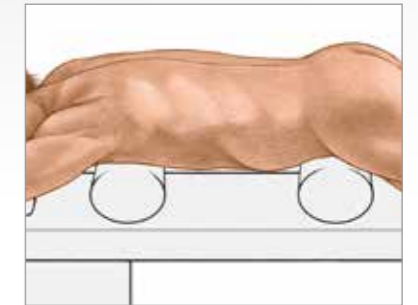
this in the case of spinal canal stenoses. The incision in the ligamentum flavum can be reduced to a few millimeters because the elasticity of the intervertebral disc facilitates entry into the spinal canal. On the other hand, mobility to the other side is equivalent to conventional operations. In a craniocaudal direction, access along adjacent levels can be considered in order to minimize the resection of structures of the spinal canal. The full endoscopic interlaminar technique permits selective operation of pathologies within the spinal canal with minimized access-related traumatization. The transforaminal access is generally the most appropriate for intradiscal, intraforaminal or extraforaminal working. The transforaminal procedure has more restrictions compared with the interlaminar approach, although it provides the best tissue conservation. The anatomical and pathological conditions mean that the percentage of transforaminal to interlaminar procedures is approximately 40 to 60 in practice.

Positioning

The patient is in the prone position lying on a pelvic and thorax roll on an X-ray permeable table. Application of a C-arc is required during the operation.

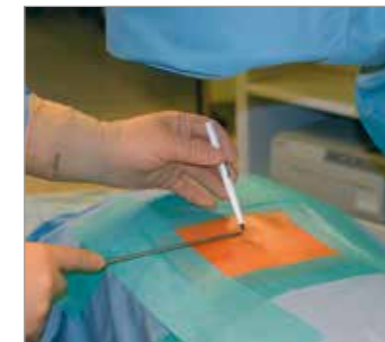

Prone position with pelvic and thorax rolls

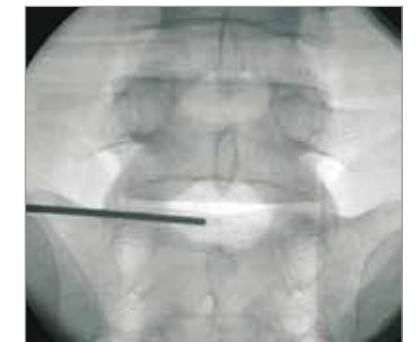

Determination of the access

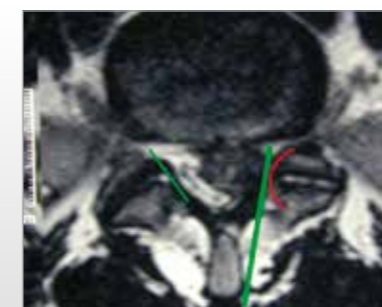
The access is determined under image intensifier control on the basis of the anatomical landmarks in the postero-anterior beam path and taking account of the pathology. It must be positioned maximally medially in the interlaminar window in order to permit entry under the obliquely positioned zygoapophyseal joints laterally.




Marking the entry point on the skin



Entry point should be in a maximally medial position



Entry under the zygoapophyseal joints should be facilitated



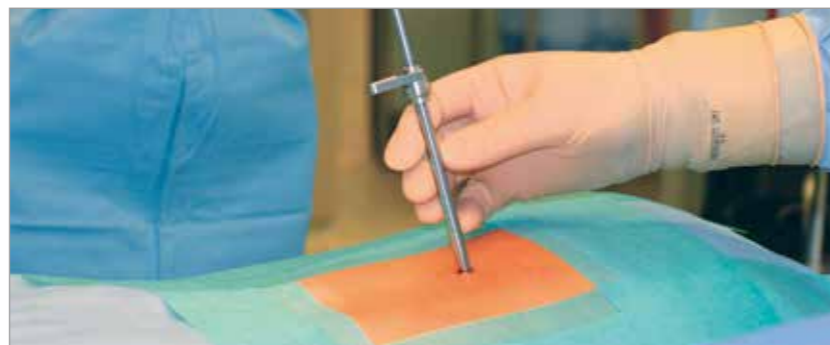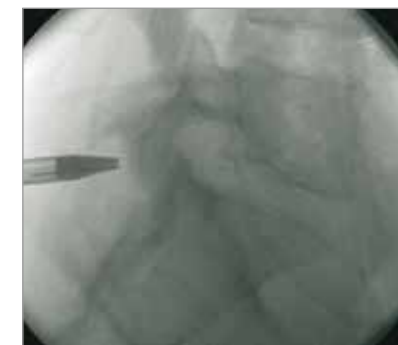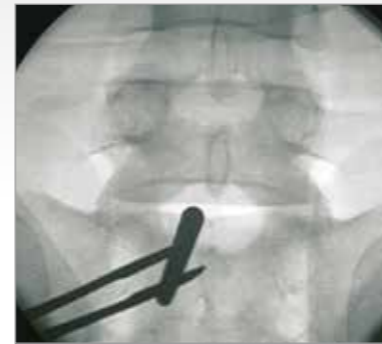Stab incision

VERTEBRIS lumbar

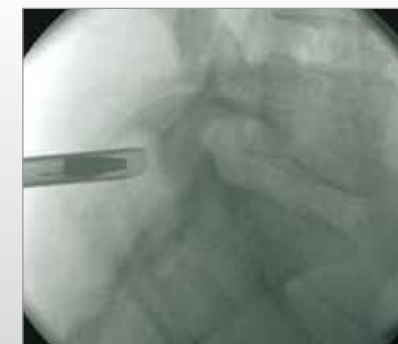
The full-endoscopic interlaminar technique

Implementation of the access

After determining the entry point in the skin and carrying out the stab incision, the dilator is inserted under posterior-anterior image intensifier control until the ligamentum flavum. The subsequent procedure is then performed in the lateral beam path. The working sleeve with oblique opening is pushed through the dilator toward the ligament and the dilator is removed.



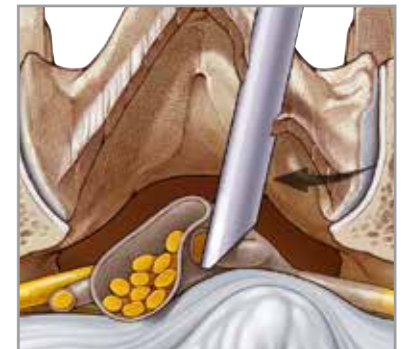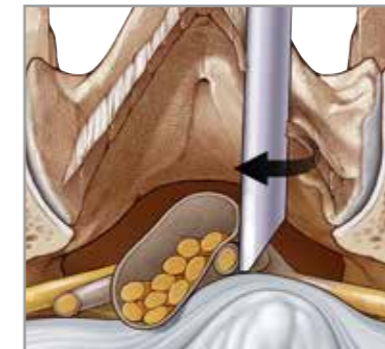
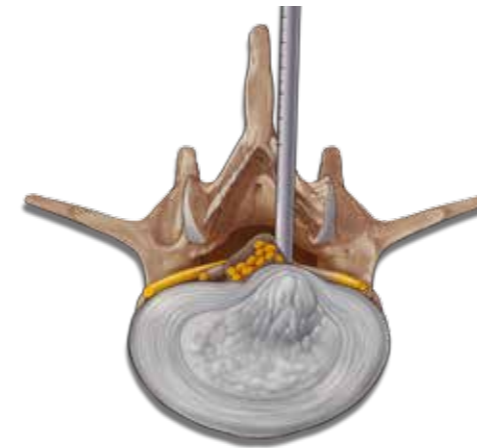
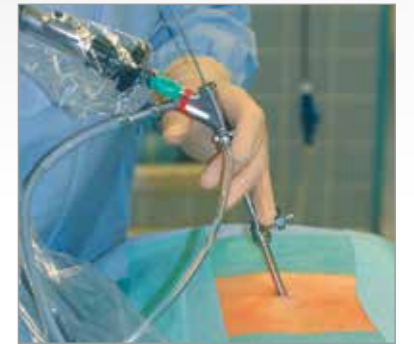Insertion of the dilator and then the sleeve under image intensifier control to the ligamentum flavum



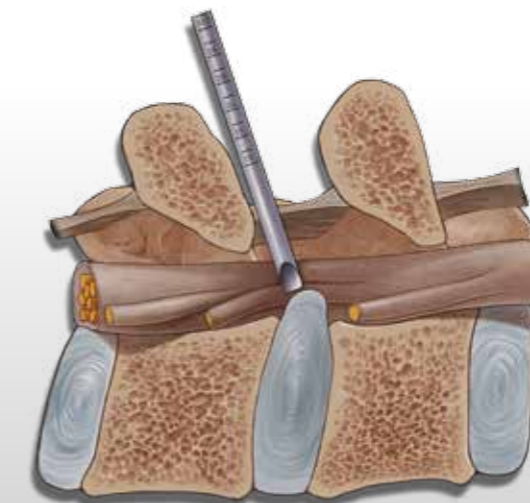
Operating procedure

The endoscope is inserted through the working sleeve. The operation is carried out in vision using different instrument sets positioned through the intraendoscopic working channel and with a continuous flow of liquid. After opening the liga-

mentum flavum, it is possible to enter the spinal canal. Mobility for the telescope is achieved by handling the visual using the joystick principle. Protection of the neural structures is provided by the beveled working sleeve serving as a second instrument and through rotation.



The beveled working sleeve can be used as a second instrument by rotation

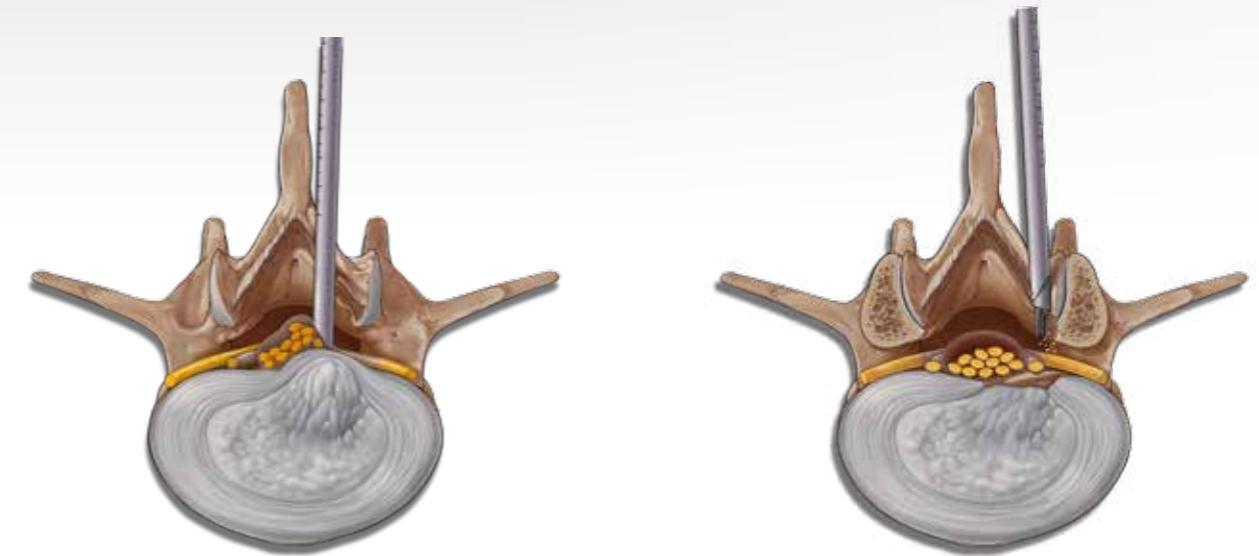
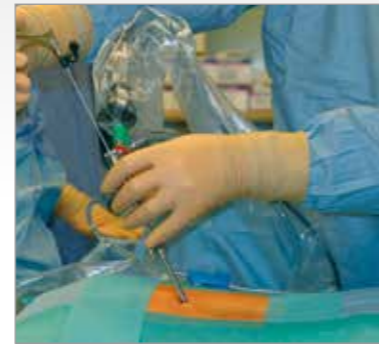

VERTEBRIS lumbar

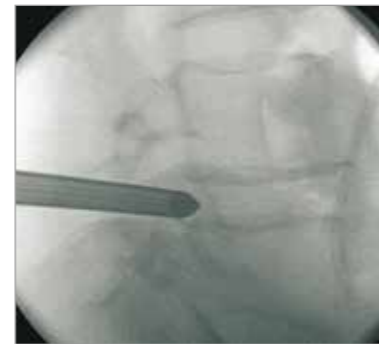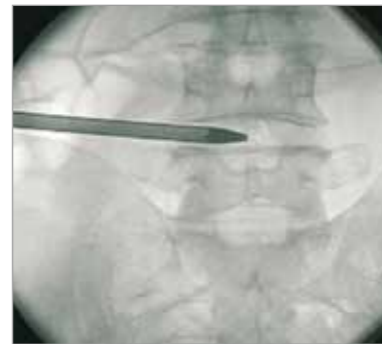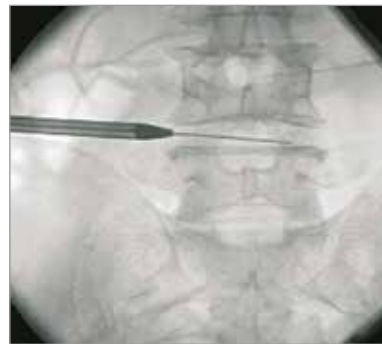The full-endoscopic interlaminar technique

The locking caps for the telescope and working sleeve should only be used briefly if bleeding obscures visibility since when operations last a long time and the drainage of fluid is prevented without being noticed, the consequences of volume overload and elevated pressure within the spinal canal and the associated and neighboring structures cannot theoretically be completely excluded. An extended and uninterrupted excessive

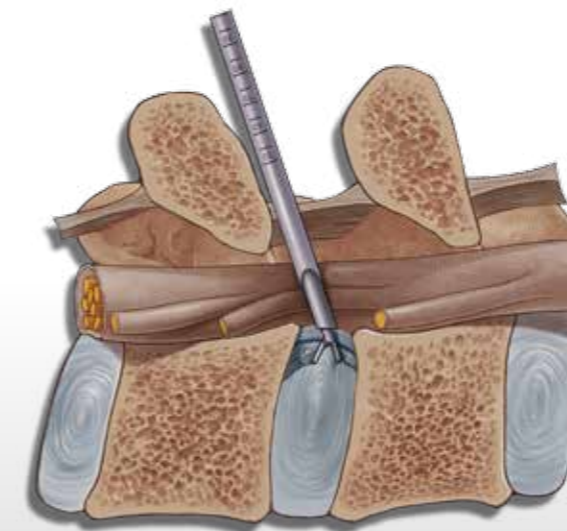
retraction of the neural structures with the working sleeve in a medial direction must be avoided particularly in cranial areas, or only carried out intermittently, in order to avoid the risk of neurological damage. Experience indicates that generally speaking there is an increased risk of complications occurring when all new procedures are carried out, in particularly during the learning curve.



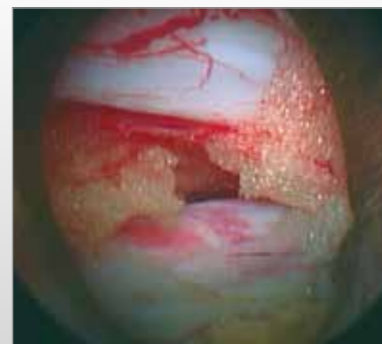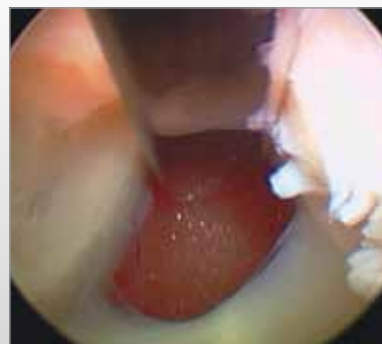A necessary bone resection is possible with the instruments and burrs available



Mobility is achieved by handling with the joystick principle



The interlaminar access permits working in the spinal canal in vision



Opening of the ligamentum flavum

View of the axilla at L5/S1

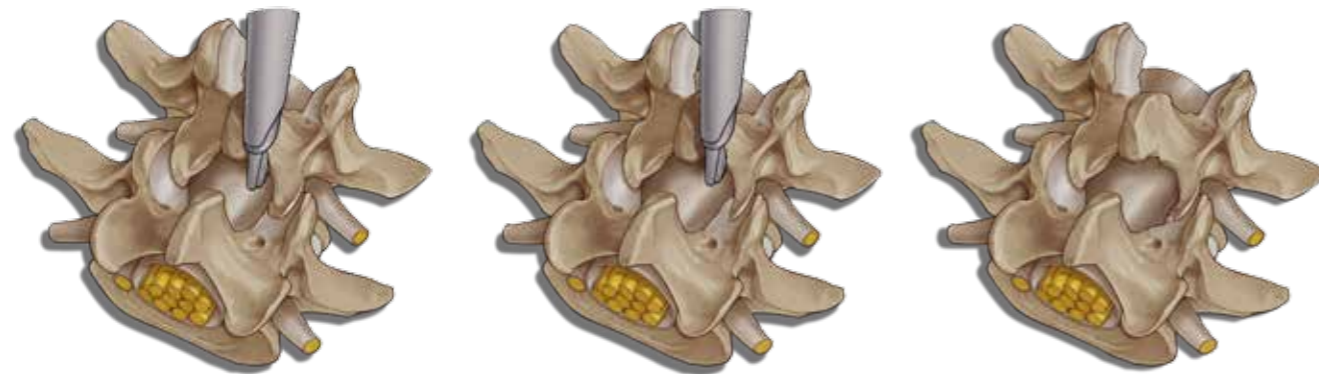
VERTEBRIS lumbar

The full-endoscopic **interlaminar** technique

Implementation of bony resection

Bone resection may be necessary in order to expand mobility within the spinal canal or if there are problems during access. This may be the case e.g. in sequestered spinal disk herniations, small interlaminar windows or during an operation on recess stenosis. After the access

has been implemented, the bony structures are dissected. It may be helpful to start decompression at the caudal end of the descending facets. Medial structures of the descending and ascending facets or the caudal and cranial laminae may be resected depending on the pathology.

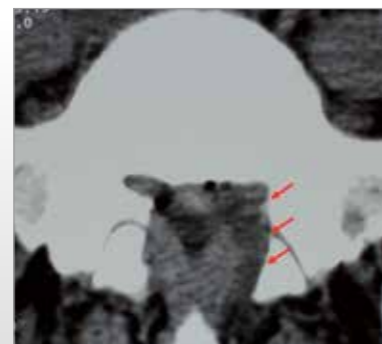


It may be helpful to start decompression at the caudal end of the descending facets

The extent of bony resection depends on the pathology



A range of burrs and bone punches are available for bone resection which can be inserted through the intraendoscopic working channel



Lateral bone resection is carried out on the floor of the spinal canal directly in the working area

VERTEBRIS lumbar

Overview of trans-/ extraforaminal and interlaminar technique

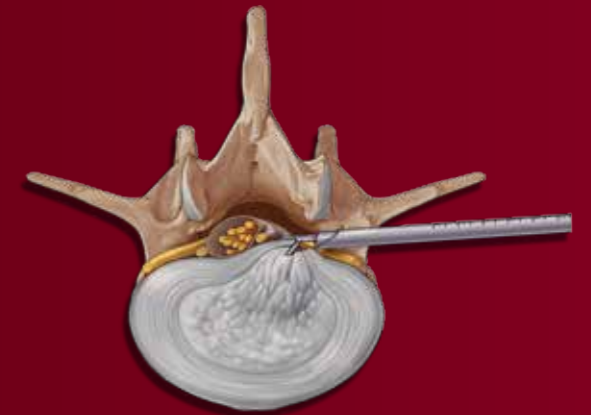
Trans- / extraforaminal technique – Access lateral

Indication criteria:

- Pathologies at level segment L4 / L5 and higher with localization intraspinal / intraforaminal / extraforaminal and intradiskal, at level L5 / S1 extraforaminal

Technical specification VERTEBRIS lumbar 8 mm:

- Access sheath OD 8.0 mm, working length 185 mm
- Working channel for instruments with outer diameter max. 4.0 mm
- Instruments with working length 360 mm



Access lateral

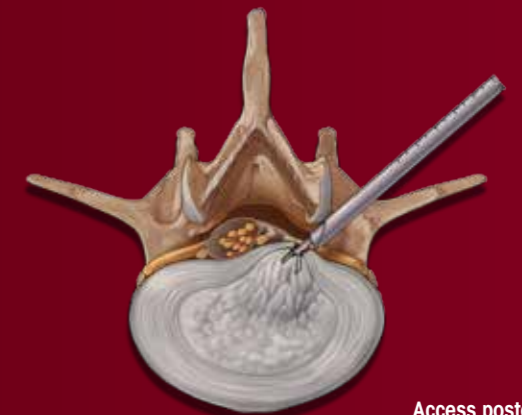Trans- / extraforaminal technique – Access posterolateral

Indication criteria:

- Pathologies at level segment L4 / L5 and higher with localization intraspinal / intraforaminal / extraforaminal and intradiskal, at level L5 / S1 extraforaminal
- Specially developed for tight anatomical conditions

Technical specification VERTEBRIS lumbar 7 mm:

- Access sheath OD 7.0 mm, working length 185 mm
- Working channel for instruments with outer diameter max. 3.0 mm
- Instruments with working length 360 mm



Access posterolateral

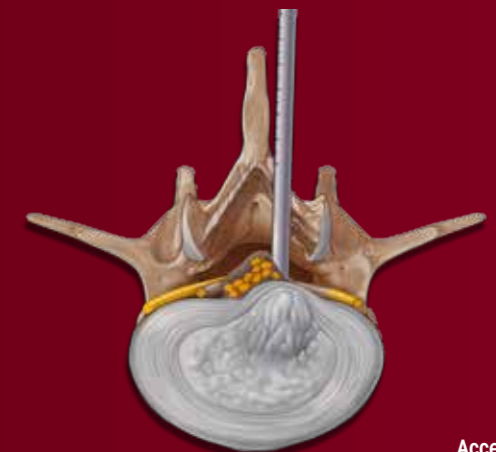
Interlaminar technique – Access posterior

Indication criteria:

- Pathologies at level segment L1 - S1, L4 / L5

Technical specification VERTEBRIS lumbar 8 mm:












- Access sheath OD 8.0 mm, working length 120 mm
- Working channel for instruments with outer diameter max. 4.0 mm
- Instruments with working length 290 mm
- Maximum mobility














Access posterior

VERTEBRIS lumbar

Instrument Set for full-endoscopic **transforaminal and extraforaminal** technique

Endoscope and accessories	
	PANOVIEW PLUS DISCOSCOPE 25° Ø 6.9 mm, SL 207 mm, rigid, with lateral ocular lens working channel Ø 4.1 mm, irrigation channel Ø 1.3 mm, GL 321 mm, rod lens system.....89210.1254
	CONE ADAPTER8791.751
	MEMBRANE ATTACHMENT8792.451
	FIBER LIGHT CABLE BNDL consisting of: 80663521 fiber Light Cable, Ø 3.5 mm, TL 2.3 m, 809509 adapter endoscope side, 809507 adapter projector side.....806635231
Access instruments reusable	
	DILATOR ID 1.3 mm, OD 6.9 mm, for single-stage dilatation, TL 235 mm89220.1508
	WORKING SLEEVE ID 7 mm, OD 8 mm, TL 186 mm, distal end beveled, graduated.....89220.1078
	FLUSHING ADAPTER For working sleeve Ø 8 mm89220.1308
	EXTENSION SLEEVE ID 7 mm, OD 8 mm, TL 155 mm89220.1408
	HAMMER8866.956
Access instruments for single use	
	PUNCTURE NEEDLE SET 18G (OD 1.25 mm), WL 150 mm, Pack = 10 PCS, sterile4792.803 18G (OD 1.25 mm), WL 250 mm, Pack = 10 PCS, sterile4792.802 17G (OD 1.5 mm), WL 250 mm, Pack = 10 PCS, sterile, for single use492201215
Instrument sieve	
	INSTRUMENT BASKET VERTEBRIS LUMBAR Sieve for sterilization, consisting of: sieve basket base, sieve basket lid, 2x locking mechanism, instrument carrier top, incl. set of silicone holders, instrument carrier bottom, incl. set of silicone holders L x W x H: 530 mm x 250 mm x 150 mm.....85841217

Instrument Set for full-endoscopic **transforaminal and extraforaminal** technique













Working instruments	
for application with endoscopes with working channel ID 4.1 mm (color coding ●●●●) and endoscopes with working channel ID 3.1 mm (color coding ●●)	
Rongeurs, grasping forceps and punches with color coding for simple identification of the instrument diameter	
	RONGEUR , WL 360 mm, reusable ● Ø 2.6 mm, TL 460 mm, with irrigation connection8792.632 ● Ø 3 mm, TL 457 mm, with irrigation connection89240.1003 ● Ø 4 mm, TL 470 mm, with irrigation connection89240.1004
	RONGEUR , extended jaw insert, WL 360 mm, reusable ● Ø 2.6 mm, TL 457 mm, with irrigation connection89240.1125
	RONGEUR , curved upward, WL 360 mm, reusable ● Ø 2.5 mm, fits in ID 4 mm working channel, TL 457 mm, with irrigation connection89240.1044
	RONGEUR , articulating, WL 340 mm, reusable ● Ø 4 mm, articulating, TL 500 mm, with irrigation connection89240.1624
	NUCLEUS GRASPING FORCEPS , WL 360 mm, reusable ● Ø 2.6 mm, TL 457 mm, with irrigation connection89230.1125 ● Ø 3 mm, TL 457 mm, with irrigation connection89230.1003 ● Ø 4 mm, TL 470 mm, with irrigation connection89230.1004
	PUNCH , WL 360 mm, reusable ● Ø 2.6 mm, TL 460 mm, with irrigation connection8792.671 ● Ø 3 mm, TL 457 mm, with irrigation connection89240.1023 ● Ø 4 mm, TL 470 mm, with irrigation connection89240.1024
	PUNCH , curved upward, WL 360 mm, reusable ● Ø 2.5 mm, TL 457 mm, fits in ID 4 mm working channel, with irrigation connection89240.1034
	SHEATH TUBE PUNCH , dismantling sheath, reusable ● Ø 3 mm, WL 360 mm, TL 450 mm, with irrigation connection89240.1903 ● Ø 4 mm, WL 357 mm, TL 500 mm, with irrigation connection89240.1904
	SCISSORS , WL 360 mm, reusable ● Ø 3 mm, TL 457 mm, with irrigation connection89240.1703
	DISSECTOR Ø 2.5 mm, WL 350 mm, atraumatic, reusable.....8792.591
	PROBE WITH FLEXIBLE TIP BNDL , consisting of: 15570643 sheath tube Ø 2.5 mm, SL 350 mm, 892501625 probe insert Ø 2 mm, 892500600 spring handle892501925

VERTEBRIS lumbar

Instrument Set for the full-endoscopic **interlaminar** technique





Endoscopes and accessories	
	PANOVIEW PLUS DISCOSCOPE 25° Ø 6.9 mm, SL 165 mm, rigid, with lateral ocular lens, working channel Ø 4.1 mm, irrigation channel Ø 1,3 mm, TL 279 mm, rod lens system 89210.3254
	ENDOSCOPE ADAPTER892009000
	CONE ADAPTER8791.751
	MEMBRANE ATTACHMENT reusable.....8792.451
	FIBER LIGHT CABLE BNDL consisting of: 80663521 fiber Light Cable, Ø 3.5 mm, TL 2.3 m, 809509 adapter endoscope side, 809507 adapter projector side.....806635231
Access instruments for discoscopes with 4.1 mm working channel	
	DILATOR ID 1.3 mm, OD 6.9 mm, TL 235 mm, for single-stage dilatation, reusable.....89220.1508
	WORKING SLEEVE ID 7 mm, OD 8 mm, TL 120 mm, distal end beveled, graduated, reusable.....89220.3008
	FLUSHING ADAPTER for working sleeve, Ø 8 mm, reusable 89220.1308
Instrument sieve	
	INSTRUMENT BASKET VERTEBRIS LUMBAR Sieve for sterilization, consisting of: sieve basket base, sieve basket lid, 2x locking mechanism, instrument carrier top, incl. set of silicone holders, instrument carrier bottom, incl. set of silicone holders L x W x H: 530 mm x 250 mm x 150 mm.....85841217






Instrument Set for the full-endoscopic **interlaminar** technique



Working instruments – interlaminar	
for application with endoscopes with working channel ID 4.1 mm (color coding ●●●●●) and endoscopes with working channel ID 3.1 mm (color coding ●●●●)	
Rongeurs, grasping forceps and punches with color coding for simple identification of the instrument diameter	
	RONGEUR , WL 290 mm, reusable ● Ø 2.6 mm, TL 388 mm, with irrigation connection 89240.2025 ● Ø 3 mm, TL 388 mm, with irrigation connection 89240.3003 ● Ø 4 mm, TL 400 mm, with irrigation connection 89240.3004
	PUNCH , WL 290 mm, reusable ● Ø 2.6 mm, TL 388 mm, with irrigation connection 89240.2225 ● Ø 3 mm, TL 388 mm, with irrigation connection 89240.3023 ● Ø 4 mm, TL 400 mm, with irrigation connection 89240.3024
	PUNCH , curved upward, WL 360 mm, reusable ● Ø 2.5 mm, TL 457 mm, fits in ID 4 mm working channel, with irrigation connection 89240.1034
	SHEATH TUBE PUNCH , dismantling tube sheath, WL 290, reusable ● Ø 3 mm, TL 380 mm, with irrigation connection 89240.3903 ● Ø 4 mm, TL 441 mm, with irrigation connection 89240.3904
	RONGEUR , curved upward, WL 360 mm, reusable ● Ø 2.5 mm, fits in ID 4 mm working channel, TL 457 mm, with irrigation connection 89240.1044
	DISSECTOR Ø 2.5 mm, WL 350 mm, atraumatic, reusable.....8792.591
	DISSECTOR Ø 3 mm, WL 350 mm, atraumatic, reusable.....89250.1003
	DISSECTOR Ø 4 mm, WL 350 mm, atraumatic, reusable.....892501004
	EXPLORING HOOK Ø 2.5 mm, WL 290 mm, atraumatic, reusable.....89250.2125
Accessories	
	POSITIONING ROD Ø 5.0 mm, WL 400 mm, graduated, pointed, reusable 8791.701
	INSTRUMENT HOLDING FORCEPS TL 208 mm.....8793.856
	SUCTION TUBE Ø 2.5 mm, WL 290 mm, reusable 89270.2025

VERTEBRIS lumbar









Instrument Set for the full-endoscopic **transforaminal posterolateral** technique

Endoscopes and accessories	
	PANOVIEW PLUS DISCOSCOPE 25° Ø 5.9 mm, SL 207 mm, rigid, with lateral ocular lens working channel Ø 3.1 mm, irrigation channel Ø 1.2 mm, TL 321 mm, rod lens system89210.1253
	CONE ADAPTER8791.751
	MEMBRANE ATTACHEMENT8792.451
	FIBER LIGHT CABLE BNDL consisting of: 80663523 fiber Light Cable, Ø 3.5 mm, TL 2.3 m, 809509 adapter endoscope side, 809507 adapter projector side806635231

Access instruments reusable	
	DILATOR ID 1.3 mm, OD 5.9 mm, for single-stage dilatation, TL 225 mm8792.764
	WORKING SLEEVE ID 6 mm, OD 7 mm, TL 186 mm, distal end beveled, graduated89220.1047
	FLUSHING ADAPTER for working sleeve Ø 7 mm89220.1307
	EXTENSION SLEEVE ID 7 mm, OD 8 mm, TL 155 mm, distal end straight89220.1407
	HAMMER8866.956





Access instruments for single use	
	PUNCTURE NEEDLE SET 18G (OD 1.25 mm), WL 150 mm, Pack = 10 PCS, sterile4792.803 18G (OD 1.25 mm), WL 250 mm, Pack = 10 PCS, sterile4792.802 17G (OD 1.5 mm), WL 250 mm, Pack = 10 PCS, sterile492201215
	INSTRUMENT BASKET VERTEBRIS LUMBAR Sieve for sterilization, consisting of: sieve basket base, sieve basket lid, 2x locking mechanism, instrument carrier top, incl. set of silicone holders, instrument carrier bottom, incl. set of silicone holders L x W x H: 530 mm x 250 mm x 150 mm85841217

Instrument Set for the full-endoscopic **transforaminal posterolateral** technique











Working instruments	
for application with endoscopes with working channel ID 4.1 mm (color coding ●●●●) and endoscopes with working channel ID 3.1 mm (color coding ●●)	
Rongeurs, grasping forceps and punches with color coding for simple identification of the instrument diameter	
	RONGEUR , WL 360 mm, reusable ● Ø 2.6 mm, TL 460 mm, with irrigation connection8792.632 ● Ø 3 mm, TL 457 mm, with irrigation connection89240.1003
	RONGEUR , WL 360 mm, reusable ● Ø 2.6 mm, TL 457 mm, with irrigation connection89240.1125
	NUCLEUS GRASPING FORCEPS , WL 360 mm, reusable ● Ø 2.6 mm, TL 457 mm, with irrigation connection89230.1125 ● Ø 3 mm, TL 457 mm, with irrigation connection89230.1003
	PUNCH , WL 360 mm, reusable ● Ø 2.6 mm, TL 460 mm, with irrigation connection8792.671 ● Ø 3 mm, TL 457 mm, with irrigation connection89240.1023
	SHEATH TUBE PUNCH , dismantling tube sheath, reusable ● Ø 3 mm, WL 360 mm, TL 450 mm, with irrigation connection89240.1903
	SCISSORS , WL 360 mm, reusable ● Ø 3 mm, TL 457 mm, with irrigation connection89240.1703
	DISSECTOR Ø 2.5 mm, WL 350 mm, atraumatic, reusable8792.591
	PROBE WITH FLEXIBLE TIP BNDL , consisting of: 15570643 sheath tube Ø 2.5 mm, SL 350 mm, 892501625 probe insert Ø 2 mm, 892500600 spring handle892501925

VERTEBRIS lumbar

Instrument Set optional






Instrument Set optional – for application through the endoscope	
Auxiliary instruments sharply abrading	
	ANNULOTOME Ø 2.5 mm, WL 350 mm, one ended, reusable.....8792.581
	FACE MILLER Ø 3 mm, WL 350 mm, sharp, reusable..... 89260.1113
	FACE MILLER Ø 4 mm, WL 350 mm, sharp, reusable.....89260.1114
Dissecting claws	
	RONGEUR , double-action jaw insert, WL 360 mm, reusable <ul style="list-style-type: none"> ● Ø 2.6 mm, GL 460 mm, with irrigation connections8792.636 ● Ø 3 mm, GL 457 mm, with irrigation connections 89240.1013 ● Ø 4 mm, GL 470 mm, with irrigation connections89240.1014
	SPREAD DISSECTOR , WL 360 mm, reusable <ul style="list-style-type: none"> ● Ø 3 mm, GL 457 mm, with irrigation connections89230.1803

Instrument Set optional




Instrument Set optional – for application through the working sleeve	
Trepines	
	
	TREPINE Ø 3 mm, WL 200 mm, sharp, reusable.....8792.503
	TREPINE Ø 5.3 mm, WL 200 mm, sharp, reusable.....8792.504
	TREPINE Ø 6.9 mm, WL 210 mm, sharp, reusable.....89260.1108
Forceps and punches, articulated	
	
	INTRADISC FORCEPS Ø 5.2 mm, WL 244 mm, color code white, TL 393 mm, with irrigation connection, reusable.....8792.623
	INTRADISC FORCEPS Ø 5.2 mm, WL 240 mm, color code white, articulated, TL 389 mm, with irrigation connection, reusable.....89240.1052
Rongeurs, punches and scissors	
	
	RONGEUR 4.3 X 5 mm, WL 247 mm, jaw section 6 mm long, TL 320 mm, reusable.....8791.691
	RONGEUR 4.3 X 4.5 mm, WL 247 mm, jaw section 12 mm long, TL 320 mm, reusable.....8791.601

VERTEBRIS lumbar

Instrument Set optional


Endoscopes	
	<p>PANOVIEW PLUS DISCOSCOPE 25° Ø 5.9 mm, SL 165 mm rigid, with lateral ocular lens, working channel Ø 3.1 mm, irrigation channel Ø 1.2 mm, TL 279 mm, rod lens system 89210.3253</p>
Access instruments	
Working sleeves for application with discoscope 89210.3253	
	<p>WORKING SLEEVE ID 6 mm, OD 7 mm, TL 120 mm, distal end beveled, graduated, reusable 89220.3007</p>
	<p>WORKING SLEEVE ID 6 mm, OD 7 mm, TL 146 mm, distal end beveled, graduated, reusable 89220.1057</p>
Working sleeves for application with discoscope 89210.1253	
	<p>WORKING SLEEVE ID 6 mm, OD 7 mm, TL 166 mm, fenestrated distal end for foraminoplasty, graduated, reusable 89220.1007</p>
	<p>WORKING SLEEVE ID 6 mm, OD 7 mm, TL 186 mm, distal end with elevator tip, graduated, reusable 89220.1157</p>
	<p>DISCOSCOPE WORKING SLEEVES BNDL, ID 6 mm, OD 7 mm, TL 166 mm, graduated, reusable consisting of: 15208255 discoscope working sleeve, with distal viewing window, 15208257 working sleeve, distal end beveled, 15208258 working sleeve, distal end with elevator tip, 15208260 working sleeve, double fenestrated distal end, 15208261 working sleeve, distal end straight 89220.1907</p>
Attachments for working sleeves OD 7.0 mm	
	<p>HANDLE ATTACHMENT for working sleeve, Ø 7 mm, reusable 89200.1007</p>





Instrument Set optional

Working sleeves for application with discoscope 89210.1254	
	<p>WORKING SLEEVE, ID 7 mm, OD 8 mm, reusable TL 186 mm, distal end beveled, graduated 89220.1078 TL 186 mm, distal end with 45° window, graduated 89220.1038 TL 166 mm, distal end with long elevation lip, graduated 89220.1068 TL 186 mm, distal end with elevation lip, graduated 89220.1088</p>
	<p>DISCOSCOPE WORKING SLEEVE BNDL, ID 7 mm, OD 8 mm, TL 166 mm, graduated, consisting of: 15208262 discoscope working sleeve, distal end beveled, 15208263 discoscope working sleeve, with distal viewing window, 15208264 discoscope working sleeve, distal end straight, 15208265 discoscope working sleeve, distal end with elevator tip, 15208266 discoscope working sleeve, fenestrated distal end for foraminoplasty 89220.1908</p>
Attachments for working sleeves OD 8 mm	
	<p>HANDLE ATTACHMENT for working sleeve, Ø 8 mm, reusable 89200.1008</p>












VERTEBRIS lumbar

Radioblator RF 4 MHz – Multidisciplinary Radiofrequency Surgical System



Radiofrequency Surgical System	
TipControl RF Instrument, bipolar, sterile for Radioblator	
	TIPCONTROL RF INSTRUMENT BIPO Ø 2.5 mm, WL 280 mm for endoscopic spine surgery, flexible insert, integrated connection cable WL 3 m with device plug to Radioblator RF 4 MHz, sterile, for single use4993691
	TIPCONTROL RF INSTRUMENT BIPO Ø 2.5 mm, WL 350 mm for endoscopic spine surgery, flexible insert, integrated connection cable WL 3 m with device plug to Radioblator RF 4 MHz, sterile, for single use4993692
TipControl RF Instrument, bipolar, sterile for US 2-PIN	
	TIPCONTROL RF INSTRUMENT BIPO Ø 2.5 mm, WL 280 mm for endoscopic spine surgery, flexible insert, integrated connection cable WL 3 m with device plug to US 2-PIN, sterile, for single use.....49936911
	TIPCONTROL RF INSTRUMENT BIPO Ø 2.5 mm, WL 350 mm for endoscopic spine surgery, flexible insert, integrated connection cable WL 3 m with device plug to US 2-PIN, sterile, for single use.....49936921








Radioblator RF 4 MHz – Multidisciplinary Radiofrequency Surgical System

Radiofrequency Surgical System	
TipControl RF Instrument, bipolar	
	TIPCONTROL RF INSTRUMENT BNDL SHORT , consisting of: 899351100 RF Electrode handle bipo, 899351010 sheath tube Ø 2.5 mm, SL 290 mm899351000
	TIPCONTROL RF ELEKTRODE BIPO Ø 2.5 mm, WL 290 mm, for endoscopic spine surgery, flexible, Pack = 5 PCS, sterile, for single use.....499351000
	TIPCONTROL RF INSTRUMENT KPL LONG , consisting of: 899351100 RF Electrode handle bipo, 899352010 sheath tube long Ø 2.6 mm899352000
	TIPCONTROL RF ELEKTRODE BIPO Ø 2.5 mm, WL 400 mm for endoscopic spine surgery, flexible, Pack = 5 PCS, sterile, for single use.....499352000
	TIPCONTROL CONNECTION CABLE BIPO WL 3 m, 2 PIN international plug, connection to EU flat plug, reusable.....899351210
Accessories	
	SHEATH TUBE Ø 2.5 mm, SL 290 mm compatible with TipControl handle bipolar, reusable.....899351010
	SHEATH TUBE Ø 3 mm, SL 290 mm compatible with TipControl handle bipolar, reusable.....899351020
	SHEATH TUBE Ø 2.6 mm, SL 400 mm compatible with TipControl handle bipolar, reusable.....899352010
	SHEATH TUBE Ø 3 mm, SL 400 mm compatible with TipControl handle bipolar, reusable.....899352020
	TIPCONTROL ANSCHLUSSKABEL BIPO WL 3 m, US 2 pin plug, connection to EU flat plug, reusable.....899351220
Radioblator RF 4 MHz 4 MHz working frequency – precisely focused and tissue presserving, monopolar and bipolar cutting and coagulation mode, program memory for 4 user presets	
	RADIOBLATOR RF 4 BNDL , consisting of: 2330001 Radioblator RF 4, 2330901 footswitch 2 pedals, 2330045 connection cable mono WL 3 m, 2440.03 power cable23300011

VERTEBRIS lumbar

Universal Motor System







Accessories for Universal Motor System – Power Drive ART1 & Power Speed AS1	
Burs	
	BURR OVAL, with lateral protection, color code violet, PACK = 1 PC, WL 350 mm, reusable Ø 2.5 mm899751502 Ø 3.0 mm899751503 Ø 4.0 mm899751504
	BURR OVAL, with front guard, color code violet, PACK = 1 PC, WL 350 mm, reusable Ø 2.5 mm899751512 Ø 3.0 mm899751513 Ø 4.0 mm899751514
	BURR ROUND, without protection, color code royal blue, PACK = 1 PC, WL 350 mm, reusable Ø 2.5 mm899751302 Ø 3.0 mm899751303 Ø 4.0 mm899751304
	DIAMOND BURR ROUND, without protection, color code light turquoise, PACK = 1 PC, WL 350 mm, reusable Ø 2.5 mm899751402 Ø 3.0 mm899751403 Ø 4.0 mm899751404
Nucleus resectors	
	NUCLEUS RESECTOR SMOOTH, color code canary yellow, PACK = 1 PC, WL 350 mm, reusable, Ø 3.0 mm899751003 Ø 4.0 mm899751004
Nucleus resectors, sterile, for single use	
	NUCLEUS RESECTOR, color code red, Ø 4.5 mm, PACK = 5 PCS, WL 240 mm.....499751045
	NUCLEUS RESECTOR CURVED, color code red, Ø 4.5 mm, PACK = 5 PCS, WL 240 mm.....499751245

Universal Motor System

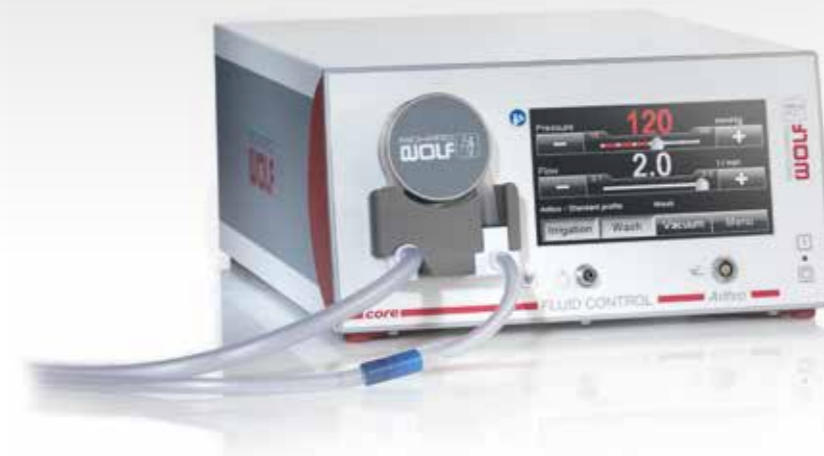Accessories for Universal Motor System Power Drive ART1 & Power Speed AS1	
Articulated burr for Power Stick M5	
	TIPControl – ARTICULATING BONE BURR BNDL, consisting of: 899753754 articulating burr Ø 4 mm, 499751704 burr insert round Ø 3.5 mm, 15261106 irrigation adapter M5, 15372005 wrench, 15336058 drive shaft M5899753794
	TIPControl – ARTICULATING BONE BURR BNDL, consisting of: 899751794 articulating burr Ø 4 mm, 499751704 burr insert round Ø 3.5 mm, 15261106 irrigation adapter M5, 15372005 wrench, 15336056 drive shaft M5899751794
	TIPCONTROL – BURR INSERT round, Ø 3.5 mm, Pack = 5 PCS, sterile, for application with TipControl articulated burr, for extraction of bony structures, sterile, for single use499751704
Tip Control Nucleus Resector	
	TIPCONTROL NUCLEUS RESECTOR ARTICULATING articulated, Ø 5.5 mm, Pack = 3 PCS, WL 350 mm, for application with the motor handles M5/0 and M5/3, for resection of soft tissue, sterile, for single use.....499751005
Motor Handles – Power Stick M5	
	POWER STICK M5/0 Motor handle max. 16000 U/min, with fixed connection cable, for use with rotation tools, control by footswitch.....899550001
	POWER STICK M5/3 Motor handle max. 16000 U/min, with fixed connection cable, for use with rotation tools, with three function buttons, control optional by footswitch899550003
Accessories for High-Speed Motor System – for use with angled handpiece for endoscopic high-speed tools	
Burr with distal protection	
	BURR ROUND, CARBIDE Ø 3.0 mm, Pack = 3 PCS, WL 353.5 mm, reusable.....82960.3730
	SHEATH TUBE WITH DISTAL GUARD Ø 4.0 mm, for endoscopic high-speed tools, WL 350 mm, reusable82970.1330
	DIAMOND BURR ROUND, DIAMOND Ø 3.0 mm, Pack = 3 PCS, WL 353.5 mm, reusable.....82960.3930
	SHEATH TUBE WITH DISTAL GUARD Ø 4.0 mm, for endoscopic high-speed tools, WL 350 mm, reusable.82970.1330
Burr without distal protection	
	DIAMOND BURR ROUND Ø 3.7 mm, Pack = 3 PCS, WL 355 mm, reusable.....82960.3940
	SHEATH TUBE Ø 4.0 mm, for endoscopic high-speed tools, WL 350 mm, reusable.82970.1340
High-Speed Handle	
	ANGLED HANDPIECE MAX. 20,000 RPM with INTRA-interface, for endoscopic tools with length 350 mm and sheath Ø 2.35 mm, reusable.82950.1301


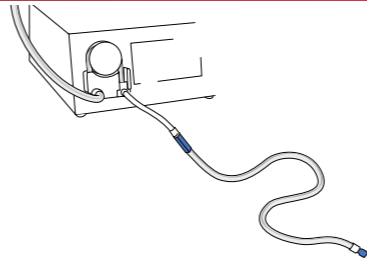
VERTEBRIS lumbar

Universal Motor System

Universal Motor System	
PowerDrive ART1 Universal Motor System: autom. handle and tool recognition, storage function with user-specific parameters and memory function for tools	
	POWERDRIVE ART1 MOTOR SYSTEM 2304 BNDL , consisting of: 2304.001 Motor Control Unit 2304, 103.701 CAN-BUS connection cable, 2440.03 power cable, power supply unit 230 V, 50/60 Hz.....23040011 2440.03 power cable, power supply unit 100 V, 50/60 Hz.....23040021 2440.03 power cable, power supply unit 110 V, 50/60 Hz.....23040041 2440.03 power cable, power supply unit 115 V, 50/60 Hz.....23040061 2440.03 power cable, power supply unit US 120 V, 50/60 Hz.....23040071 2440.03 power cable, power supply unit 127 V, 50/60 Hz.....23040121 2440.03 power cable, power supply unit 240 V, 50/60 Hz.....23040141
	FOOTSWITCH 2 PEDALS for Power Drive ART1 Motor Control Unit (2304)2304.901
PowerSpeed AS1 Universal Motor System: autom. handle and tool recognition, storage function with user-specific parameters and memory function for tools	
	POWERSPEED AS1 MOTOR CONTROL UNIT 2305 Universal Motor System for orthopedics, spine surgery and bronchoscopy, for connection of motor handle M4. M5/O. M5/3. S1. M1 and high-speed motor X1, connection for two handpieces and a footswitch, 6.5" touch screen color display, compatible with core nova, for orthopedics, spine surgery and bronchoscopy, for connection of motor handle M4. M5/O. M5/3. S1. M1 and high-speed motor X1, connection for two handpieces and a footswitch, 6.5" Touch Screen color display, compatible with core nova, power supply unit 100-240V, 50/60 Hz.....2305001
	WIRELESS FOOTSWITCH for PowerSpeed AS1 generator (2305)2305100 with: charger for wireless footswitch2305200 backup cable for wireless footswitch2305300

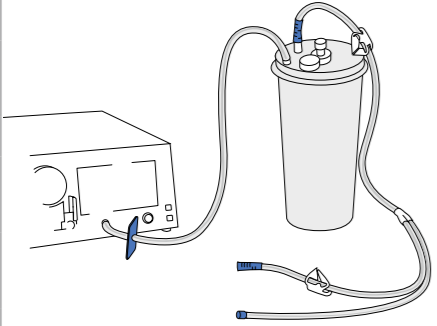
FLUID CONTROL Arthro-Spine – Innovative Fluid Management System







Fluid Management System	
Fluid Control Arthro-Spine irrigation and suction pump with software module spine mode for arthroscopy and full-endoscopic spine surgery with automatic tube recognition	
	FLUID CONTROL ARTHRO-SPINE 2204 BNDL , consisting of: 2204101 spine mode software module, 2204001 Fluid Control Arthro-Spine suction and irrigation pump 200 mmHg, 8171223 irrigation tube set spike, 8170.401 vacuum tube, 4171.121 protection filter for gas filtration, 2440.03 power cable22040012
Irrigation	
	Accessories – reusable IRRIGATION TUBE SET SPIKE incl. 20 replacement sealing membranes, silicone, Pack = 1 PC, with 2 piercing spikes, 20x reusable, for Fluid Control Arthro/Spine 2204 and Fluid Control Lap 22168171223
Accessories – for single use, sterile	
IRRIGATION TUBE SET SPIKE L 3 m, with Y-piece, PVC, Pack = 10 PCS, for Fluid Control Arthro/Spine 2204 and Fluid Control Lap 22164171223	
IRRIGATION TUBE SET CARE LOCK L 3 m, with Y-piece, PVC, Pack = 10 PCS, for Fluid Control Arthro/Spine 2204 and Fluid Control Lap 22164171224	

VERTEBRIS lumbar

FLUID CONTROL Arthro-Spine – Innovative Fluid Management System

Suction / Evacuation	
	Accessories – reusable VACUUM TUBE silicone, for connection of vacuum (pump) with suction container8170.401
	SUCTION CONTAINER 3 L, includes mounting bracket.....8170.981
	Accessories – for single use SUCTION CONTAINER 3 L, Pack = 2 PCS2215.971
	TUBE SET L 5 m, with Y-shape piece, PVC, Pack = 10 PCS, sterile4170.901
	PROTECTIVE FILTER FOR GAS FILTRATION sterile4171.121

Consumables and Accessories	
	MEMBRANE 15479006
	IRRIGATION LEVER, CPL 15461.034
	REPLACEMENT O-RING 15461,034, PACK = 10 PCS9500.113
	O-RING 15364285

Literature

Komp M, Hahn P, Oezdemir S, Giannakopoulos A, Heikenfeld R, Kasch R, Merk H, Godolias G, Puchstein C, Ruetten S. Bilateral decompression of lumbar central stenosis using the full-endoscopic interlaminar technique compared with microsurgical technique: A prospective, randomized, controlled study. *Pain Physician* 2015; 18:61-70

Ruetten S, Komp M, Oezdemir S. Current status of full-endoscopic techniques in the surgical treatment of disk herniations and spinal canal stenosis. *Chinese Journal of Bone and Joint* 2014; 3:571-584

Komp M, Hahn P, Oezdemir S, Merk H, Kasch R, Godolias G, Ruetten S. Operation of lumbar zygoapophyseal joint cysts using a full-endoscopic interlaminar and transforaminal approach: prospective 2-year results of 74 patients. *Surg Innov* 2014; 21:605-14

Ruetten S, Komp M, Hahn P, Oezdemir S. Decompression of lumbar lateral spinal stenosis: full-endoscopic, interlaminar technique. *Oper Orthop Traumatol* 2013;DOI 10.1007/s00064-012-0195-2

Ruetten S, Komp M, Hahn P. Endoscopic disk and decompression surgery. In: Haertl R, Korge A (eds) *AO Spine - Minimally Invasive Spine Surgery – Techniques, Evidence, and Controversies*. Thieme, Stuttgart New York 2012, pp 315-330

Ruetten S. Equipment for full-endoscopic spinal surgery. In: Vieweg U, Grochulla F (eds) *Manual of Spine Surgery*. Springer, Heidelberg, New York, Dordrecht, London 2012,pp 59-62

Ruetten S. Endoscopic lumbar disk surgery. In: Vieweg U, Grochulla F (eds) *Manual of Spine Surgery*. Springer, Heidelberg, New York, Dordrecht, London 2012, pp 303-308

Ruetten S. Full-endoscopic operations of the spine in disk herniations and spinal stenosis. *Surg Technol Int* 2011;XXI:284-298

Ruetten S. Full-endoscopic interlaminar lumbar discectomy and spinal decompression. In: Kim DH, Kim K-H, Kim Y-C (eds) *Minimally Invasive Percutaneous Spinal Techniques*. Elsevier, Philadelphia, 2011, pp 351-359

Komp M, Hahn P, Merk H, Godolias G, Ruetten S. Bilateral operation of lumbar degenerative central spinal stenosis in full-endoscopic interlaminar technique with unilateral approach: Prospective 2-year results of 74 patients. *J Spinal Disord Tech* 2011;24:281-287

Ruetten S, Komp M, Merk H, Godolias G. Surgical treatment for lumbar lateral recess stenosis with the full-endoscopic interlaminar approach versus conventional microsurgical technique: A prospective, randomized, controlled study. *J Neurosurg Spine* 2009;10:476-485

Ruetten S, Komp M, Merk H, Godolias G. Recurrent lumbar disk herniation following conventional discectomy: A prospective, randomized study comparing full-endoscopic interlaminar and transforaminal versus microsurgical revision. *J Spinal Disord Tech* 2009;22:122-129

Kuonsongtum V, Paiboonsirijit S, Kesornsak W, Chaiyosboorana V, Rukskul P, Chumnanvej S, Ruetten S. Result of full-endoscopic uniportal lumbar discectomy: Preliminary report. *J Med Assoc Thai* 2009;6:776-780

Ruetten S, Komp M, Merk H, Godolias G. Full-endoscopic anterior decompression versus conventional anterior decompression and fusion in cervical disk herniations. *Int Orthop* 2008;33:1677,DOI 10.1007/s00264-008-0684-y

Ruetten S, Komp M, Merk H, Godolias G. Full-endoscopic cervical posterior foraminotomy for the operation of lateral disk herniations using 5.9-mm endoscopes: A prospective, randomized, controlled study. *Spine* 2008;33:940-948

Ruetten S, Komp M, Merk H, Godolias G. Full-endoscopic interlaminar and transforaminal lumbar discectomy versus conventional microsurgical technique: A prospective, randomized, controlled study. *Spine* 2008;33:931-939

Ruetten S, Komp M, Merk H, Godolias G. A new full-endoscopic technique for cervical posterior foraminotomy in the treatment of lateral disk herniations using 6.9-mm endoscopes: prospective 2-year results of 87 patients. *Minim Invas Neurosurg* 2007;50:219-226

Ruetten S, Komp M, Merk H, Godolias G. Use of newly developed instruments and endoscopes: full-endoscopic resection of lumbar disk herniations via the interlaminar and lateral transforaminal approach. *J Neurosurg Spine* 2007;6:521-530

Ruetten S. Full-endoscopic operations of lumbar disk herniations with transforaminal and interlaminar approach. *European Musculoskeletal Review* 2007;69-72

Ruetten S, Komp M, Godolias G. A new full-endoscopic technique for the interlaminar operation of lumbar disk herniations using 6 mm endoscopes: Prospective 2-year results of 331 patients. *Minim Invasive Neurosurg* 2006; 49:80-87

Ruetten S, Komp M, Godolias G. An extreme lateral access for the surgery of lumbar disk herniations inside the spinal canal using the full-endoscopic uniportal transforaminal approach. Technique and prospective results of 463 patients. *Spine* 2005;30:2570-2578

Ruetten S, Komp M, Godolias G. Full-endoscopic interlaminar operation of lumbar disk herniations using new endoscopes and instruments. *Orthop Praxis* 2005;10:527-532

Ruetten S. The full-endoscopic interlaminar approach for lumbar disk herniations. In: Mayer HM (ed) *Minimally Invasive Spine Surgery*. Springer, Berlin Heidelberg, New York, 2005, pp 346-355

Ruetten S, Meyer O, Godolias G. Endoscopic surgery of the lumbar epidural space (epiduroscopy): Results of therapeutic intervention from 93 patients. *Minim Invas Neurosurg* 2003;46:1-4

Ruetten S, Meyer O, Godolias G. Application of Holmium: YAG Laser in Epiduroscopy: Extended Practicabilities in the Treatment of Chronic Back Pain Syndrome. *J Clin Laser Med Surg* 2002; 20:203-206

Ruetten S, Meyer O, Godolias G. Epiduroscopic Diagnosis and Treatment of Epidural Adhesions at Chronic Back Pain Syndrome of Patients with Previous Surgical Treatment: First Results of 26 Interventions. *Z Orthop* 2002; 140:171-175

we perform
innovation